Downloaded from www.ajronline.org by 167.61.156.69 on 10/03/17 from IP address 167.61.156.69. Copyright ARRS. For personal use only; all rights reserved

Pediatric Abdominal Radiographs: Common and Less Common Errors

Sarah J. Menashe[1]
Ramesh S. Iyer
Marguerite T. Parisi
Randolph K. Otto
Edward Weinberger
A. Luana Stanescu

OBJECTIVE. Interpretation of abdominal radiographs of children benefits from a firm knowledge of the congenital anomalies and pathologies unique to this patient population, leveraged by a systematic approach. Interpretive errors place the patients and their families at risk for a delay in diagnosis, unnecessary additional imaging, a potential increase in the radiation burden, and possible psychologic trauma.

CONCLUSION. In this article, we describe the common and uncommon potential pitfalls in pediatric abdominal radiography, using several of our own interpretive errors as a framework while providing teaching points to help avoid these mistakes.

The concept that medical errors contribute to patient morbidity and mortality was widely substantiated by the Institute of Medicine in 1999, when its report *To Err Is Human: Building a Safer Health System* was published [1]. The numbers quoted at the time seemed staggering, but they have continued to increase, with medical errors most recently reported as the third leading cause of death in the United States [2].

As in all fields of medicine, errors in radiology are often multifactorial, may be perceptual (i.e., the finding was not seen), may be caused by insufficient characterization (i.e., the finding was identified but its significance was not appropriately recognized), or may represent a failure in communication (i.e., the finding was accurately reported but the appropriate channels of communication for notifying the provider were not used), among many other causes [3, 4]. Growing awareness of imaging errors has led to an increased focus on identifying, understanding, and avoiding these mistakes, not only in the radiology literature as a whole but, more recently, in pediatric radiology as well [3, 4–6].

At our institution, as part of a rigorous quality assurance program, we use various peer review strategies to identify such errors and promote ongoing continuous education and feedback [7, 8]. These strategies include monthly peer review conferences and peer review scorecards that assist in closing the feedback loop to interpreting radiologists. Although peer review methods or scorecards are critically important as educational tools, a more extended discussion of these tools is beyond the intended scope of this article. Instead, using a case-based approach, we offer examples of some of our own "missed" cases to illustrate common and less common errors that may occur, specifically when interpreting abdominal radiographs of pediatric patients.

The Abdomen

Causes of abdominal pathology in the pediatric population can differ significantly from those in the adult population, and they are further confounded by the inability of a young patient to adequately communicate or localize symptoms. Differential considerations in the pediatric subset also vary among age groups, where neonates, infants, and young children can have distinctly different causes of abdominal pathology. Imaging evaluation may consequently require any combination of advanced techniques, including ultrasound, fluoroscopy, CT, and MRI. Nevertheless, the most commonly performed initial examination remains the abdominal radiograph. Despite its widespread use, particularly in the emergency department, the sensitivity and specificity of abdominal radiography are quite variable [9–11]. Pitfalls may arise because of difficulties in obtaining patient cooperation or because of the use of an image acquisition technique that is inadequate for the size of the patient's body.

Keywords: abdominal radiographs, errors, pediatric

DOI:10.2214/AJR.17.17889

Received December 30, 2016; accepted January 18, 2017.

Based on a presentation at the ARRS 2016 Annual Meeting, Toronto, ON, Canada.

[1]All authors: Department of Radiology, Seattle Children's Hospital, University of Washington, 4800 Sand Point Way NE, MA.7.220, Seattle, WA 98105. Address correspondence to A. L. Stanescu (stanescu@u.washington.edu).

AJR 2017; 209:417–429

0361–803X/17/2092–417

© American Roentgen Ray Society

Downloaded from www.ajronline.org by 167.61.156.69 on 10/03/17 from IP address 167.61.156.69. Copyright ARRS. For personal use only; all rights reserved

Such pitfalls may occasionally ensnare even the most seasoned pediatric radiologist [7]. Therefore, having a good command of common and less common pediatric abdominal pathologies and their associated imaging findings is essential when assessing abdominal radiographs.

Technique and Approach

Historically, both supine and upright views of the abdomen were routinely acquired in the setting of acute abdominal symptoms. Recent heightened awareness of radiation and its potential long-term consequences has caused radiologists and clinicians alike to rethink the necessity of obtaining multiple views in all clinical contexts. For example, a single supine anteroposterior abdominal radiograph is often all that is necessary to characterize suspected constipation, which is a common cause of pediatric abdominal pain. If obstruction, perforation, or some other pathology is suspected, additional projections may be appropriate, and they may include left lateral decubitus or cross-table lateral projections, for young children, or more conventional supine and upright views, for older pediatric patients [12]. An anteroposterior image should include the lung bases and the diaphragm superiorly, extend to the inferior pubic rami inferiorly, and encompass both abdominal walls along the lateral edge. A thorough interpretation algorithm includes careful scrutiny of the bowel gas pattern, assessment for the presence of abdominal calcifications or mass effect, solid-organ evaluation, identification of extraluminal collections of gas or fluid, and attention to osseous structures [10, 12].

Bowel Gas Pattern

There is significant heterogeneity in the normal bowel gas pattern seen among adults and children alike, in part related to the variability of air and the fluid-filled small bowel. Additional variation will be present in healthy neonates on the first day of life, when the bowel gas pattern is dependent on swallowed air moving distally from the stomach to the small intestine to the sigmoid colon, normally over 8–9 hours [13]. Persistent displacement of bowel loops, unusual distribution of bowel gas, or the presence of dilated gas-filled bowel loops may indicate underlying pathology [14].

Case 1

Case 1 involved a 2-year-old girl with a 4- to 5-month history of intermittent fevers and a 1-week history of abdominal distention (Fig. 1).

Discussion—An abdominal mass identified in the first year of life is most commonly of renal origin and has benign causes, such as hydronephrosis or multicystic dysplastic kidney, which are usually detected on prenatal ultrasound. During the ensuing decade of life, however, primary tumors of the kidney become more common in children, with Wilms tumor reported to be the most common abdominal malignancy in childhood [15], followed by neuroblastoma. Clear cell sarcoma of the kidney, historically known as bone metastasizing renal tumor of infancy, represents less than 4–5% of primary renal tumors and typically occurs before the age of 4 years. Commonly presenting as an abdominal mass and often indistinguishable from Wilms tumor on imaging, clear cell sarcoma is more aggressive and is associated with higher mortality and relapse rates [16].

Although an overall paucity of bowel gas or gasless abdomen has been reported in association with intubation in neonates [17], observation of decreased or displaced bowel gas in an infant or child should prompt careful scrutiny of the adjacent soft tissues for any abnormality.

Teaching point—Abdominal radiographs that show persistent displacement of bowel loops on multiple views should raise the concern for the presence of an abdominal mass.

Case 2

Case 2 involved a 4-week-old boy (born prematurely at 27 weeks of gestation) with a history of heart block requiring a pacemaker and respiratory failure. The patient presented with increased fussiness (Fig. 2).

Discussion—In infants and children, inguinal hernias are one of the most common reasons for surgery. This is especially true for premature infants, for whom both the incidence and risk of an incarcerated hernia is the highest [18–20]. Inguinal hernias are more common in male patients, with reported ratios ranging from 3:1 to 10:1 [21]. In premature infants, timing of the surgical intervention is controversial and is dependent on gestational age, birth weight, the risk of incarceration, and the underlying health of the infant [19].

An inguinal hernia may present clinically as scrotal swelling or a groin mass with or without evidence of bowel obstruction. On properly performed abdominal radiographs, gas-filled bowel loops may be seen herniating below the inguinal ligament, sometimes with additional findings of bowel distention. The recognition and description of the hernia are important because a delay in diagnosis can lead to an increased risk of incarceration with obstruction and perforation [12].

Evaluation of bowel obstruction in children can be difficult because bowel loop size can vary depending on the age of the child; for example, a normally distended bowel loop in a toddler could represent significant bowel dilatation in a premature infant. In 1980, Edwards [22] proposed using fixed bony landmarks to allow more accurate assessment of bowel dilatation, regardless of patient size. Bowel loops were considered to be normal in diameter when measuring less than the combined height of the L1 and L2 vertebral bodies, including the intervening disk space. Once dilated bowel loops are identified, one should search for clues to their underlying cause, starting first with whether the obstruction is proximal (indicated by the presence of few loops present) or distal (indicated by the presence of multiple loops). Bowel obstructions in pediatric patients may be secondary to a number of causes, including adhesions, appendicitis, intussusception, inguinal hernia, malrotation with midgut volvulus and Meckel diverticulum (easily remembered using the mnemonic AAIIMM), among numerous other causes [23–25].

Teaching point—Inguinal hernias are an important cause of bowel obstruction in children. The presence of gas-filled bowel below the inguinal canal should be documented, even in the absence of signs of obstruction. Also, when a bowel obstruction is suspected in a child, it is important to try to characterize the level of obstruction, generally proximal versus distal.

Case 3

Case 3 involved a 21-year-old woman with a history of acute lymphoblastic leukemia after bone marrow transplantation who presented with fever and cough (Fig. 3).

Discussion—Pneumatosis intestinalis (PI) is defined as the presence of gas within the bowel wall. Although visible on a variety of imaging modalities, it is often first detected on abdominal radiography [26, 27]. Intramural gas may be focal or diffuse, and on radiography it appears as linear, curvilinear, or rounded bubbly lucencies [28]. In neonates, PI has classically been associated with necrotizing enterocolitis, which is often a life-threatening and surgical emergency. However, in older pediatric patients, the causes and

Downloaded from www.ajronline.org by 167.61.156.69 on 10/03/17 from IP address 167.61.156.69. Copyright ARRS. For personal use only; all rights reserved

TABLE 1: Risk Factors for Pneumatosis in Pediatric Patients

Risk Factor	Description
Transplantation	Solid organ, bone marrow
Immunosuppression	AIDS, steroid use, chemotherapy
Short-gut syndrome	
Infection	
Obstruction	Volvulus, hypertrophic pyloric stenosis, constipation
Chronic pulmonary disease	Asthma, cystic fibrosis
Rheumatologic and collagen vascular diseases	Systemic lupus erythematosus, juvenile dermatomyositis, juvenile idiopathic arthritis
Congenital heart disease	
Malignancy	Leukemia and lymphoma
Drugs	Steroids and chemotherapy

Note—Data are from [26, 27, 31, 32].

associated clinical conditions are quite varied, ranging from potentially life-threatening to benign [26, 27, 29–31] (Table 1).

Among older children, PI is often found in those who are immunosuppressed as a result of chemotherapy, solid-organ or bone marrow transplantation, or treatment for autoimmune diseases. Obstructive pulmonary disease, congenital heart disease, and short-gut syndrome are other common predisposing conditions [29, 32]. When PI is identified, it is important to document its location, extent, and severity as well as the presence of any more ominous secondary findings, including the presence of portal venous gas or frank pneumoperitoneum. However, it is important to note that among older pediatric patients, findings of PI are not specific for a particular cause or even indicative of disease severity. Clinical correlation is necessary to appropriately contextualize the findings [31, 32].

In neonates with pneumatosis and necrotizing enterocolitis, treatment and indications for surgical intervention are largely standardized [28]. However, in older infants and children, management of pneumatosis is dependent on the cause, ranges from conservative bowel rest and antibiotics to emergent surgery, and is determined in large part on the basis of clinical status rather than on any one particular imaging finding [26, 31].

Teaching point—Extraluminal gas in a bubbly or curvilinear pattern along the bowel wall representing pneumatosis may occur for many reasons, not all of which are worrisome. Correlation with clinical context (e.g., a preterm neonate with bloody stools or a teenager with leukemia and immunosuppression) is particularly important when detecting pneumatosis.

Peritoneal Cavity

The peritoneal cavity is a potential space found between the visceral peritoneum, which lines the visceral organs, and the parietal peritoneum, which lines the abdominal wall. Abnormal accumulation of air or fluid within this potential space can occur in pediatric patients for a number of reasons. Familiarity with the numerous signs of peritoneal pathology on abdominal radiography is important for the appropriate diagnosis and management of these patients.

Case 4

Case 4 involved a 6-week-old boy who underwent a Blalock-Taussig shunt procedure for tetralogy of Fallot. Increased irritability raised clinical concern for possible pneumatosis related to necrotizing enterocolitis, given the patient's recent cardiac surgery (Fig. 4).

Discussion—Pneumoperitoneum may have a wide variety of causes, ranging from iatrogenic causes, such as recent abdominal surgery or endoscopic procedures, to life-threatening hollow viscus perforation [33]. The radiographic findings may be subtle and easily overlooked, particularly on a supine radiograph or for a patient for whom clinical suspicion is low. Familiarity with the varied manifestations of free intraperitoneal air on abdominal or chest radiographs is vital for successful identification [34]. When considering the possibility of pneumoperitoneum, it is helpful to organize the radiographic signs into broad categories, including those that are bowel related independent of location, those that are localized within the right upper quadrant or related to the peritoneal ligaments, and those that are categorized as belonging to other patterns [34] (Table 2).

When a patient is imaged in the supine position, air within the peritoneal cavity will preferentially accumulate in a nondependent fashion under the central tendon of the diaphragm and median subphrenic space. Air in this region may be the only manifestation of minimal pneumoperitoneum. When seen as an arcuate lucency caudal to the heart, it is known as the cupola sign [33, 35]. More frequently, free air is indicated by the presence of a hyperlucent liver (i.e., a hyperlucent liver sign) and rounded or oval lucencies projecting over the liver (i.e., superior oval sign) [34].

If there is high clinical suspicion or radiographic uncertainty regarding the presence of free air on initial images, images in the upright and left lateral decubitus views should be obtained. Ideally, these images should be obtained after the patient has been in the erect or left lateral decubitus position for several minutes, enabling the detection of as little as 1–2 mL of free air. With such attention to technique, upright and left lateral decubitus radiographs have sensitivities greater than 85% and 96%, respectively [33, 34].

Teaching point—Familiarity with the common locations and manifestations of pneumoperitoneum is requisite, particularly in critically ill children. As a rule of thumb, the soft-tissue attentuation of the liver on a radiograph of a patient in a supine position should be homogeneous. The presence of sharp interfaces delineating central regions of hypodensity should raise concern for pneumoperitoneum. Artifacts from overlying devices that cannot be removed at the time of imaging may occasionally obscure pneumoperitoneum.

Case 5

Case 5 involved an 11-year-old girl with abdominal distention and lethargy that occurred 1 month after the patient underwent total colectomy for ulcerative colitis (Fig. 5).

A companion case involved a 13-year-old girl with a history of constipation and suprapubic pain (Fig. 6).

Discussion—Ascites, or the abnormal accumulation of fluid in the peritoneal cavity, has numerous causes in infants and children [36, 37]. Possible radiographic signs are similarly abundant and are specific, although variably sensitive, often requiring large amounts of ascites to be present for a diagnosis to be made. Signs include generalized haziness of the abdomen, medial displace-

Downloaded from www.ajronline.org by 167.61.156.69 on 10/03/17 from IP address 167.61.156.69. Copyright ARRS. For personal use only; all rights reserved

TABLE 2: Signs of Pneumoperitoneum

Sign	Description
Bowel-related signs	
Rigler sign	Visualization of both sides of bowel wall; requires large amounts of pneumoperitoneum to be visible
Triangle sign	Free air among three adjoining bowel loops, or two bowel loops and adjacent peritoneum
Right upper quadrant signs	
Hyperlucent liver	Relative hypodensity of air collection anterior to the ventral hepatic surface replaces brightness of hepatic shadow
Anterior superior oval	Numerous round, oval, or pear-shaped lucencies projecting over liver shadow
Fissure for ligamentum teres	Visualization of extrahepatic portion of the ligamentum teres
Doge cap	Triangular focus of free air that accumulates in Morison pouch
Hepatic edge	Saucer- or cigar-shaped collection of air running along the inferior right subhepatic space, following liver contour
Dolphin sign	Air outlining the long costal muscle slips of the diaphragm and projecting over the liver
Peritoneal ligament related signs	
Falciform ligament	Linear density of the falciform ligament outlined by air in the right upper abdomen
Inverted V	Two lateral umbilical ligaments in the pelvis outlined by air create an inverted "v"
Urachus	Thin dense linear midline structure that runs from the bladder dome to the umbilicus
Other	
Football	Large oval radiolucency creates sharp interface with parietal peritoneum
Cupola	Arcuate lucency that overlies the lower thoracic spine, seen just inferior to the heart
Subphrenic lucency	Radiolucency seen below either hemidiaphragm

Note—Data are from [34, 64].

ment of the edge of the liver (i.e., Hellmer sign), and centralization of bowel loops, among other signs. The most sensitive and specific sign reportedly is the liver edge sign, where there is loss of the lower margin of the right lateral edge of the liver [18].

Teaching point—Ascites can manifest radiographically by centralization of bowel loops and increased overall abdominal density.

Calcifications

Although there are many common and incidental sources of calcifications in adult patients (e.g., arterial calcification, phleboliths, and cholelithiasis), the same cannot be said for pediatric patients. As such, the search for abnormal calcifications on radiographs is particularly important when assessing infants and children, in whom etiological factors range from benign renal calculi to tumoral calcifications, such as those that occur in neuroblastoma [38].

Case 6

Case 6 involved a 2-year-old boy who presented with vomiting (Fig. 7).

Discussion—When evaluating calcifications, location and morphologic findings can offer clues as to the cause, with patient age and symptoms helping to further narrow the differential diagnosis. For example, in neonates, calcifications that are seen diffusely within the peritoneal cavity (distributed over the liver and the right upper quadrant or seen peripherally around a peritoneal pseudocyst) suggest in utero bowel perforation with subsequent meconium peritonitis or meconium pseudocyst formation [39]. When more focal triangular-shaped calcifications are noted in the region of the adrenal gland, a remote adrenal hemorrhage should be considered and is generally seen in neonates or in early childhood. When focal calcifications project over the kidneys, the bladder, or the expected course of the ureters, collecting system calculi should be suspected, more commonly occurring in the older child who presents with flank pain or in the setting of a neurogenic bladder.

Neuroblastoma is a primary consideration in the differential diagnosis for retroperitoneal calcifications and may be associated with a soft-tissue mass, occasionally presenting with elevation of the ipsilateral hemidiaphragm or inferior displacement of the ipsilateral kidney [40]. Neuroblastoma is a tumor of neural crest origin and can arise anywhere along the sympathetic nervous system; it is considered a tumor of infancy and early childhood, with 50% of patients presenting by age 2 years and nearly 90% by 8 years [40]. The most common primary site is the abdomen (in 65% of patients), either adrenal or retroperitoneal, with an abdominal mass noted as the most frequently occurring clinical presentation, although additional constitutional symptoms are often present [41, 42]. On radiographs, an abdominal mass with bowel gas displacement may be seen. Of note, calcifications are present on up to 60% of radiographs of children with neuroblastoma [42].

Teaching point—When the radiographic appearance suggests abdominal calcifications, a broad differential diagnosis must be considered, including dense ingested intraluminal contents.

Case 7

Case 7 involved an 11-day-old boy with a history of repaired congenital diaphragmatic hernia who had undergone intubation (Fig. 8).

Discussion—The differential diagnosis for abdominal calcifications, as discussed in the preceding case, broadens in neonates who have undergone umbilical venous catheter placement, because vascular or parenchymal injury may occur [43]. Ideally, an umbilical venous catheter should course from the umbilicus in a midline location along the anterior abdominal wall through the umbilical vein, extending superiorly and posteriorly as it courses through the umbilical recess to reach the left portal vein. The catheter should then progress through the ductus venosus and turn cephalad toward the inferior vena cava (IVC). Appropriate placement of the tip of the catheter is generally considered to be in the supradiaphragmatic portion of the IVC or at the junction of the IVC and right atrium [43]. Although uncommon, serious hepatic complications can arise in the setting

Downloaded from www.ajronline.org by 167.61.156.69 on 10/03/17 from IP address 167.61.156.69. Copyright ARRS. For personal use only; all rights reserved

of a malpositioned umbilical venous catheter used for total parenteral nutrition; therefore, knowledge of the expected course and tip position is critical [44].

Complications of abnormal umbilical venous catheter placement may include subcapsular hematoma, hepatic fluid collections or abscess, parenchymal necrosis, laceration, and biliary venous fistula. Thrombosis, a complication that can occur even when the umbilical venous catheter is correctly positioned, may be silent or may present acutely with distal lower limb swelling and thrombocytopenia [45]. Once calcified, a thrombus can be detected on a radiograph or by sonography, and it is often seen along the expected course of the umbilical venous catheter in the right upper quadrant [43].

Teaching point—Unlike in adults, in whom soft-tissue calcifications are often related to senescent changes or incidental findings, abdominal calcifications are frequently associated with pathology in pediatric patients and often require further investigation. As such, both their presence and location should be documented.

Bones

Although abdominal radiographs generally are not obtained for evaluation of the skeleton, evaluation of the included ribs, lumbosacral spine, and pelvis should be an integral part of image interpretation. Congenital and developmental abnormalities are often identified in the neonatal and pediatric population [12], with unsuspected bony malignancies and infection occasionally revealed. The radiologist must be familiar with entities that are unique to children and their typical radiographic findings.

Case 8

Case 8 involved a 12-year-old girl who had intermittent right-sided flank pain for 3 months (Fig. 9).

Discussion—Bone pain in the pediatric population is common and frequently benign. Common pathologic causes of bone pain in children include trauma and infection, as well as neoplasm or neoplasticlike processes, many of which can have overlapping symptoms and imaging characteristics [46].

Diagnosis may be challenging, given confounding symptoms and the difficulty in obtaining a detailed history from young children. As such, imaging is often requested to supplement clinical history, physical examination, and laboratory tests. In the setting of vague symptoms and referred pain, a chest or abdominal radiograph is often the first imaging study obtained. Visualized bony structures should be evaluated for integrity as well as for the presence of lytic or sclerotic bony lesions or simply abnormal bone density.

Ewing sarcoma of bone is one of the most common primary bone malignancies in childhood, second only to osteosarcoma [47]. Originally described by James Ewing in 1921, it is part of the Ewing sarcoma family of tumors, which includes tumors originating in soft tissue that were previously known as primitive neuroectodermal tumor as well as Askin tumors, which are a group of cytogenetically linked cancers [48].

The presenting symptoms will be variable and will depend on tumor location, but they are commonly insidious and of prolonged duration [49]. Fever and an elevated erythrocyte sedimentation rate may mimic infection, while in fact representing a harbinger of advanced local disease and metastases [48].

On radiographs, destructive or permeative intramedullary changes with ill-defined borders are common findings, although the lesion may also have a mixed lytic-sclerotic or entirely sclerotic appearance. An associated aggressive, lamellated, or spiculated periosteal reaction and soft-tissue mass are also frequently observed, with the latter often out of proportion to the degree of bone destruction observed [42, 46, 48, 49]. Ewing sarcoma may infrequently present with subtle changes in bone density or even without abnormal osseous radiographic findings, despite the large size of the tumor.

The major differential considerations for a lytic aggressive bone lesion include osteosarcoma, infection, and Langerhans cell histiocytosis, all of which require prompt diagnosis for optimal treatment [48, 49].

Teaching point—The skeleton should be scrutinized on abdominal radiographs because osseous pathology may present with referred abdominal or pelvic pain, and abdominal radiography may be the first imaging study performed. A wide spectrum of bony findings may be encountered, ranging from subtle changes in bone mineralization with minimal lucencies or sclerosis to aggressive bony lesions, which may represent an underlying infectious or neoplastic process.

Case 9

Case 9 involved a 14-week-old boy who was born prematurely and who had undergone bowel resection for necrotizing enterocolitis (Fig. 10).

Discussion—Developmental dysplasia of the hip (DDH) refers to the spectrum of abnormalities related to abnormal growth and development of the hip, whether involving the femoral head, the acetabulum, or both. The term encompasses all causes of dysplasia, subluxation, or frank dislocation, and the condition may be congenital (in which case it is known as primary DDH and is considered most common) or developmental (in which case it is known as teratologic DDH and is related to underlying neurologic, connective tissue, or syndromic causes) [50].

The overall incidence of DDH ranges from one to five cases per 1000 live births, although this number increases with certain predisposing factors, including, but not limited to, breech presentation, female sex, oligohydramnios, firstborn status, and positive family history [51–53].

Although DDH is considered highly treatable when caught early, a missed or late diagnosis is often challenging to manage and can lead to significant disability [51]. However, modes of screening remain controversial, with some experts advocating universal ultrasound for neonates, while others recommend a thorough history and physical examination as the primary tool, reserving imaging for cases for which risk factors or clinical findings warrant its use [51, 52, 54]. According to the 2009 American College of Radiology Appropriateness Criteria, evaluation for DDH should occur at every infant visit during the first year of life, where inquiry into risk factors and a physical examination, including the Ortolani and Barlow maneuvers, will help determine whether further assessment is warranted [55].

Radiographs are thought to have limited value in the evaluation of mild dysplasia early in postnatal life because the femoral heads are composed nearly entirely of radiolucent cartilage up until 4–6 months of age. Although frank dislocation may be obvious, subtle cases of dysplasia may be suggested by the asymmetric size or position of the femoral head ossification centers. In cases of bilateral hip dysplasia, the radiologist will need to rely on other findings for diagnosis [55]. If dysplasia is suspected but ossified femoral heads are not yet present, ultrasound is the diagnostic tool of choice for infants younger than 6 months [56].

Teaching point—Assessment of the hip joints on abdominal radiographs is important, particularly in younger nonambulatory children in whom hip subluxation may be not be evident clinically.

Downloaded from www.ajronline.org by 167.61.156.69 on 10/03/17 from IP address 167.61.156.69. Copyright ARRS. For personal use only; all rights reserved

Case 10

Case 10 involved a 6-month-old boy who had constipation since birth (Fig. 11).

Discussion—Functional constipation, or constipation without known cause, is thought to affect 3% of the pediatric population worldwide, with up to 40% of patients presenting in the first year of life [57]. Although most affected children fall into this idiopathic category, a thorough clinical history and physical examination may reveal an underlying disorder that is not always readily apparent at birth [57, 58].

The term "sacral agenesis" applies to the congenital absence of all or part of the sacrum. When isolated, it has been reported to occur in the setting of maternal diabetes, although a cause often cannot be determined. Association with certain syndromes, such as VACTERL (vertebral anomalies, anal atresia, cardiac abnormalities, tracheoesophageal fistula, with or without esophageal atresia, and renal and limb anomalies) and OEIS (omphalocele, exstrophy of the cloaca, imperforate anus, and spinal defects), has also been well established. An autosomal dominant form of sacral agenesis exists as well, with its most severe phenotype including complete absence of the sacrum or a hemisacrum, presacral mass, and anorectal malformation [59, 60]. Approximately 300 cases of this triad, first described in 1981 by Currarino and colleagues [60], have since been reported in the literature. The current literature suggests that Currarino syndrome may be a more appropriate term because additional anomalies of the urogenital and müllerian duct systems are often present; although less common, concomitant Hirschsprung disease has also been reported [60, 61]. Other frequent associations include spinal dysraphism and tethering of the spinal cord [62]. Depending on the severity of anomalies, patients may present with anorectal malformation at birth or with bowel obstruction, urinary retention, or incontinence later in childhood [62].

As a general rule, five ossified sacral segments are present at birth in a term neonate and can be well visualized on radiography [63]. With Currarino syndrome, however, the so-called scimitar sacrum is often seen, with preservation of the first sacral segment and sickle- or crescent-shaped deformity of the more caudal sacrum evident on radiographs [59]. Spinal ultrasound can be obtained until the patient is 4 months of age and may show abnormal or absent sacral and coccygeal ossification centers as well as a cystic or solid presacral mass. The conus may also be low lying. MRI will better evaluate any presacral lesion as well as the extent of any underlying dysraphism, while also confirming the location of the conus.

Teaching point—When a child undergoes abdominal radiography for constipation, one must be certain to assess sacral integrity.

Conclusion

Radiography is frequently used for children who have indications similar to those seen in adults, albeit with a host of unique potential pathologies. A comprehensive understanding of the anatomy is requisite for identifying subtle extraluminal air and abdominal masses. In addition, identifying congenital anomalies and sequelae of in utero insults is helpful in directing further care. Last, it is important to remember that abnormalities in the upper abdomen are frequently overlooked on chest radiographs. We offer these examples of diagnostic errors as a framework by which one may implement a more systematic interpretive approach and may potentially reduce the frequency and impact of these pitfalls in the future.

References

1. Kohn LT, Corrigan JM, Donaldson MS, eds. *To err is human: building a safer health system*. Washington, DC: National Academy Press, Institute of Medicine, 1999
2. Makary MA, Daniel M. Medical error—the third leading cause of death in the US. *BMJ* 2016; 353:i2139
3. Brady A, Laoide RÓ, McCarthy P, McDermott R. Discrepancy and error in radiology: concepts, causes and consequences. *Ulster Med J* 2012; 81:3–9
4. Taylor GA, Voss SD, Melvin PR, Graham DA. Diagnostic errors in pediatric radiology. *Pediatr Radiol* 2011; 41:327–334
5. Engelkemier DR, Taylor GA. Pitfalls in pediatric radiology. *Pediatr Radiol* 2015; 45:915–923
6. Menashe SJ, Iyer RS, Parisi MT, Otto RK, Stanescu AL. Pediatric chest radiographs: common and less common errors. *AJR* 2016; 207:903-911
7. Stanescu AL, Parisi MT, Weinberger E, Ferguson MR, Otto RK, Iyer RS. Peer review: lessons learned in a pediatric radiology department. *Curr Probl Diagn Radiol* 2016; 45:139-148
8. Iyer RS, Swanson JO, Otto RK, Weinberger E. Peer review comments augment diagnostic error characterization and departmental quality assurance: 1-year experience from a children's hospital. *AJR* 2013; 200:132–137
9. Freedman SB, Thull-Freedman J, Manson D, et al. Pediatric abdominal radiograph use, constipation, and significant misdiagnoses. *J Pediatr* 2014; 164:83.e2–88.e2
10. Daneman A, Navarro OM. Common pitfalls in paediatric abdominal imaging. *Pediatr Radiol* 2009; 39(suppl 3):369–371
11. Zeina AR, Shapira-Rootman M, Mahamid A, Ashkar J, Abu-Mouch S, Nachtigal A. Role of plain abdominal radiographs in the evaluation of patients with non-traumatic abdominal pain. *Isr Med Assoc J* 2015; 17:678–681
12. James B, Kelly B. The abdominal radiograph. *Ulster Med J* 2013; 82:179–187
13. Berrocal T, Lamas M, Gutiérrez J, Torres I, Prieto C, del Hoyo ML. Congenital anomalies of the small intestine, colon, and rectum. *RadioGraphics* 1999; 19:1219–1236
14. Musson RE, Bickle I, Vijay RK. Gas patterns on plain abdominal radiographs: a pictorial review. *Postgrad Med J* 2011; 87:274–287
15. Geller E, Kochan PS. Renal neoplasms of childhood. *Radiol Clin North Am* 2011; 49:689–709
16. Lowe LH, Isuani BH, Heller RM, et al. Pediatric renal masses: Wilms tumor and beyond. *RadioGraphics* 2000; 20:1585–1603 erratum in *RadioGraphics* 2001; 21:766]
17. Kassner EG, Koo EL, Harper RG, Rose JS. Gasless abdomen in neonates with orotracheal tubes. *Radiology* 1974; 112:659–667
18. Bundrick TJ, Cho SR, Brewer WH, Beachley MC. Ascites: comparison of plain film radiographs with ultrasonograms. *Radiology* 1984; 152:503–506
19. Crankson SJ, Al Tawil K, Al Namshan M, et al. Management of inguinal hernia in premature infants: 10-year experience. *J Indian Assoc Pediatr Surg* 2015; 20:21–24
20. de Goede B, Verhelst J, van Kempen BJ, et al. Very low birth weight is an independent risk factor for emergency surgery in premature infants with inguinal hernia. *J Am Coll Surg* 2015; 220:347–352
21. Lee J, Scampoli N. Incarcerated ovarian inguinal hernia in a 10-month-old girl. *CMAJ* 2015; 187:596–598
22. Edwards DK. Size of gas-filled bowel loops in infants. *AJR* 1980; 135:331–334
23. Hajivassiliou CA. Intestinal obstruction in neonatal/pediatric surgery. *Semin Pediatr Surg* 2003; 12:241–253
24. Anantha Sathyanarayana S, Deutsch GB, Friedman B. An interesting cause of mechanical small bowel obstruction. *Indian J Surg* 2015; 77(suppl 2):731–732
25. Mirza B. Perforated appendicitis presenting as small bowel obstruction in an infant. *APSP J Case Rep* 2011; 2:26
26. Feczko PJ, Mezwa DG, Farah MC, White BD. Clinical significance of pneumatosis of the bowel wall. *RadioGraphics* 1992; 12:1069–1078

Downloaded from www.ajronline.org by 167.61.156.69 on 10/03/17 from IP address 167.61.156.69. Copyright ARRS. For personal use only; all rights reserved

27. Chang CY, Marzan KA. Benign pneumatosis intestinalis in a pediatric patient with multiple risk factors including granulomatosis with polyangiitis: a case report and review of the literature. *Semin Arthritis Rheum* 2015; 44:423–427
28. Epelman M, Daneman A, Navarro OM, et al. Necrotizing enterocolitis: review of state-of-the-art imaging findings with pathologic correlation. *RadioGraphics* 2007; 27:285–305
29. Cruz AT, Naik-Mathuria BJ, Bisset GS. Pneumatosis intestinalis in a corticosteroid-dependent child. *J Emerg Med* 2015; 48:607–608
30. Miyamae T, Ishiguro N, Yonezawa M, Tokushige K, Yamanaka H. Pneumatosis intestinalis associated with juvenile dermatomyositis. *Case Rep Rheumatol* 2016; 2016:6497357[Epub 2016 May 8]
31. Kurbegov AC, Sondheimer JM. Pneumatosis intestinalis in non-neonatal pediatric patients. *Pediatrics* 2001; 108:402–406
32. Fenton LZ, Buonomo C. Benign pneumatosis in children. *Pediatr Radiol* 2000; 30:786–793
33. Marshall GB. The cupola sign. *Radiology* 2006; 241:623–624
34. Chiu YH, Chen JD, Tiu CM, et al. Reappraisal of radiographic signs of pneumoperitoneum at emergency department. *Am J Emerg Med* 2009; 27:320–327
35. Mindelzun RE, McCort JJ. The cupola sign of pneumoperitoneum in the supine patient. *Gastrointest Radiol* 1986; 11:283–285
36. Lane ER, Hsu EK, Murray KF. Management of ascites in children. *Expert Rev Gastroenterol Hepatol* 2015; 9:1281–1292
37. Griscom NT, Colodny AH, Rosenberg HK, Fliegel CP, Hardy BE. Diagnostic aspects of neonatal ascites: report of 27 cases. *AJR* 1977; 128:961–969
38. Friedman AP, Haller JO, Boyer B, Cooper R. Calcified portal vein thromboemboli in infants: radiography and ultrasonography. *Radiology* 1981; 140:381–382
39. Lee GS, Chandran S, Rajadurai VS. Calcified meconium pseudocyst: x-ray diagnosis of meconium peritonitis at birth. *BMJ Case Rep* 2015; July 7:2015
40. David R, Lamki N, Fan S, et al. The many faces of neuroblastoma. *RadioGraphics* 1989; 9:859–882
41. Chu CM, Rasalkar DD, Hu YJ, Cheng FW, Li CK, Chu WC. Clinical presentations and imaging findings of neuroblastoma beyond abdominal mass and a review of imaging algorithm. *Br J Radiol* 2011; 84:81–91
42. Dickson PV, Sims TL, Streck CJ, et al. Avoiding misdiagnosing neuroblastoma as Wilms tumor. *J Pediatr Surg* 2008; 43:1159–1163
43. Schlesinger AE, Braverman RM, DiPietro MA. Pictorial essay: neonates and umbilical venous catheters—normal appearance, anomalous positions, complications, and potential aid to diagnosis. *AJR* 2003; 180:1147–1153
44. Sherwani P, Vire A, Anand R, Jajoo M. Umbilical venous catheterization gone wrong: hepatic complications. *Indian J Radiol Imaging* 2016; 26:40–43
45. Park CK, Paes BA, Nagel K, Chan AK, Murthy P; Group TaHiNT. Neonatal central venous catheter thrombosis: diagnosis, management and outcome. *Blood Coagul Fibrinolysis* 2014; 25:97–106
46. McCarville MB. The child with bone pain: malignancies and mimickers. *Cancer Imaging* 2009; 9 Spec No A:S115–S121
47. Balamuth NJ, Womer RB. Ewing's sarcoma. *Lancet Oncol* 2010; 11:184–192
48. Murphey MD, Senchak LT, Mambalam PK, Logie CI, Klassen-Fischer MK, Kransdorf MJ. From the radiologic pathology archives: Ewing sarcoma family of tumors—radiologic-pathologic correlation. *RadioGraphics* 2013; 33:803–831
49. Maheshwari AV, Cheng EY. Ewing sarcoma family of tumors. *J Am Acad Orthop Surg* 2010; 18:94–107
50. Guille JT, Pizzutillo PD, MacEwen GD. Development dysplasia of the hip from birth to six months. *J Am Acad Orthop Surg* 2000; 8:232–242
51. Kotlarsky P, Haber R, Bialik V, Eidelman M. Developmental dysplasia of the hip: what has changed in the last 20 years? *World J Orthop* 2015; 6:886–901
52. Bache CE, Clegg J, Herron M. Risk factors for developmental dysplasia of the hip: ultrasonographic findings in the neonatal period. *J Pediatr Orthop B* 2002; 11:212–218
53. Atalar H, Gunay C, Yavuz OY, Camurdan AD, Uras I, Eren A. Maternal height and infant body mass index are possible risk factors for developmental dysplasia of the hip in female infants. *Acta Med Okayama* 2015; 69:349–354
54. Güler O, Şeker A, Mutlu S, Çerçi MH, Kömür B, Mahiroğulları M. Results of a universal ultrasonographic hip screening program at a single institution. *Acta Orthop Traumatol Turc* 2016; 50:42–48
55. Karmazyn BK, Gunderman RB, Coley BD, et al. ACR Appropriateness Criteria on developmental dysplasia of the hip: child. *J Am Coll Radiol* 2009; 6:551–557
56. Noordin S, Umer M, Hafeez K, Nawaz H. Developmental dysplasia of the hip. *Orthop Rev (Pavia)* 2010; 2:e19
57. Tabbers MM, DiLorenzo C, Berger MY, et al. Evaluation and treatment of functional constipation in infants and children: evidence-based recommendations from ESPGHAN and NASPGHAN. *J Pediatr Gastroenterol Nutr* 2014; 58:258–274
58. Phipps KD, Wrogemann J, El-Matary W. A rare cause of chronic constipation. *Gastroenterology* 2016; 150:1090–1091
59. Lynch SA, Wang Y, Strachan T, Burn J, Lindsay S. Autosomal dominant sacral agenesis: Currarino syndrome. *J Med Genet* 2000; 37:561–566
60. Buyukbese Sarsu S, Parmaksiz ME, Cabalar E, Karapur A, Kaya C. A very rare cause of anal atresia: Currarino syndrome. *J Clin Med Res* 2016; 8:420–423
61. Kim SH, Paek SH, Kim HY, Jung SE, Park KW. Currarino triad with müllerian duct anomaly in mother and daughter without *MNX1* gene mutation. *Ann Surg Treat Res* 2016; 90:49–52
62. Kole MJ, Fridley JS, Jea A, Bollo RJ. Currarino syndrome and spinal dysraphism. *J Neurosurg Pediatr* 2014; 13:685–689
63. Beek FJ, Bax KM, Mali WP. Sonography of the coccyx in newborns and infants. *J Ultrasound Med* 1994; 13:629–634
64. Pinto A, Miele V, Schillirò ML, et al. Spectrum of signs of pneumoperitoneum. *Semin Ultrasound CT MR* 2016; 37:3–9

(Figures start on next page)

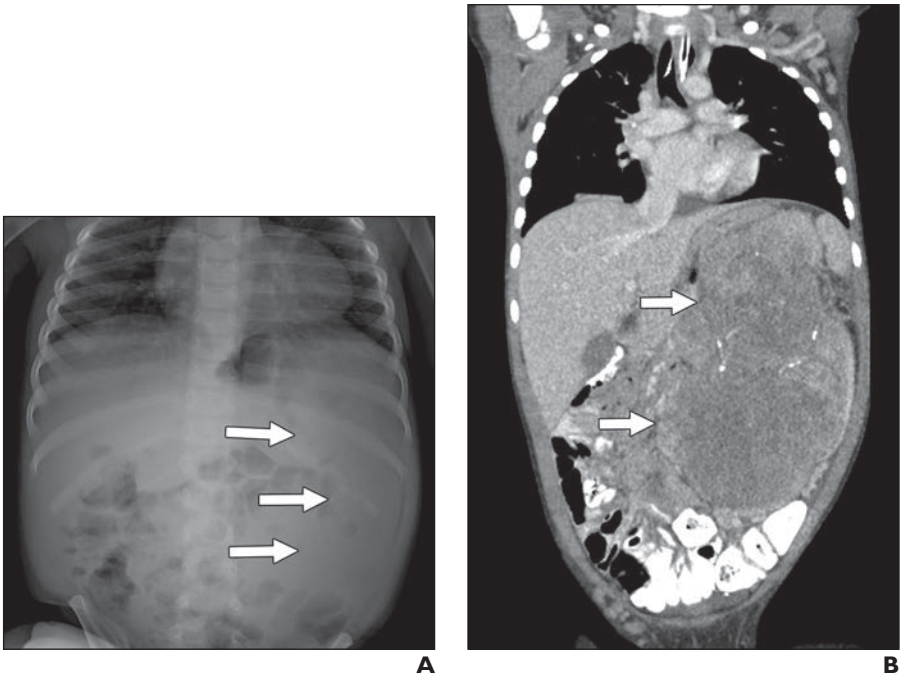

Fig. 1—2-year-old girl with 4- to 5-month history of intermittent fevers and one-week history of abdominal distention.
A, Initial abdominal radiograph obtained at outside institution missed focal paucity of bowel gas (*arrows*) with medial displacement of bowel loops in left upper abdomen. Subtle calcifications in this region were difficult to visualize. Subsequent ultrasound examination (not shown) revealed left-sided abdominal mass.
B, Contrast-enhanced CT obtained for staging shows large multilobulated mass (*arrows*) with linear calcifications in left renal fossa. Mass invaded left kidney and completely replaced left renal parenchyma. Pathologic analysis revealed clear cell sarcoma of kidney.

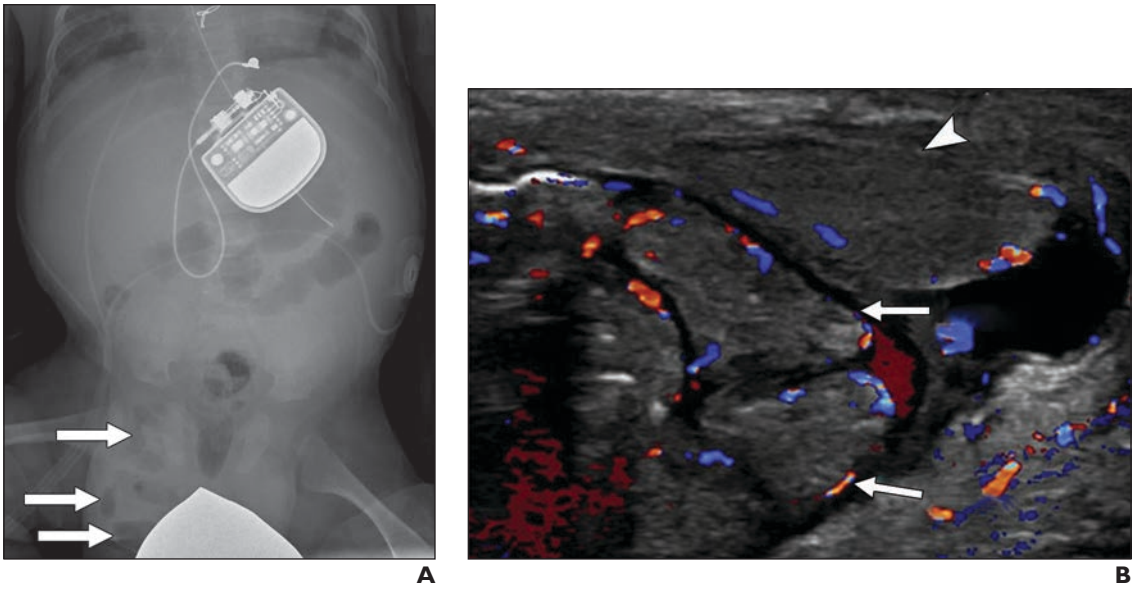

Fig. 2—4-week-old boy (born prematurely at 27 weeks of gestation) who had history of heart block requiring pacemaker and of respiratory failure. Patient presented with increased fussiness.
A, Abdominal radiograph shows right inguinal hernia containing gas-filled bowel loops (*arrows*), which initially was not reported. Pacemaker is also seen.
B, Color Doppler ultrasound image obtained 1 day after radiograph in **A** because of clinical concern for incarcerated hernia shows large right inguinal hernia containing small bowel loops (*arrows*) with normal perfusion on color-flow imaging, which was nonreducible in real-time imaging. Right testicle (*arrowhead*) shows normal perfusion, and small hydrocele is also present.

Downloaded from www.ajronline.org by 167.61.156.69 on 10/03/17 from IP address 167.61.156.69. Copyright ARRS. For personal use only; all rights reserved

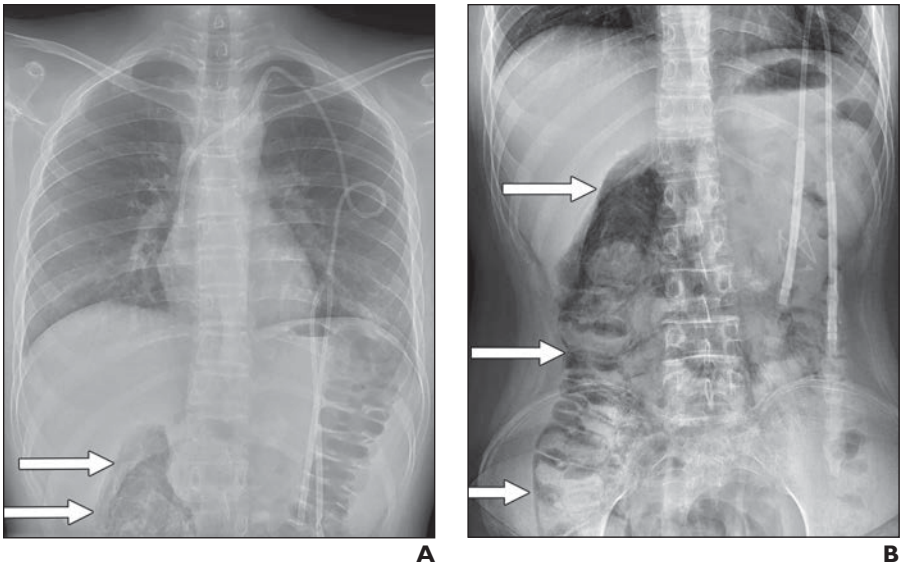

Fig. 3—21-year-old woman with history of acute lymphoblastic leukemia after bone marrow transplantation who presented with fever and cough.
A, Initial chest radiograph shows pneumatosis (*arrows*) along right colon at hepatic flexure, which was initially missed.
B, Abdominal radiograph obtained 2 days after radiograph in **A** because of abdominal pain in setting of persistent cough. Image shows increased extent of pneumatosis (*arrows*) along visualized right and proximal transverse colon. Pneumatosis resolved with antibiotics and bowel rest.

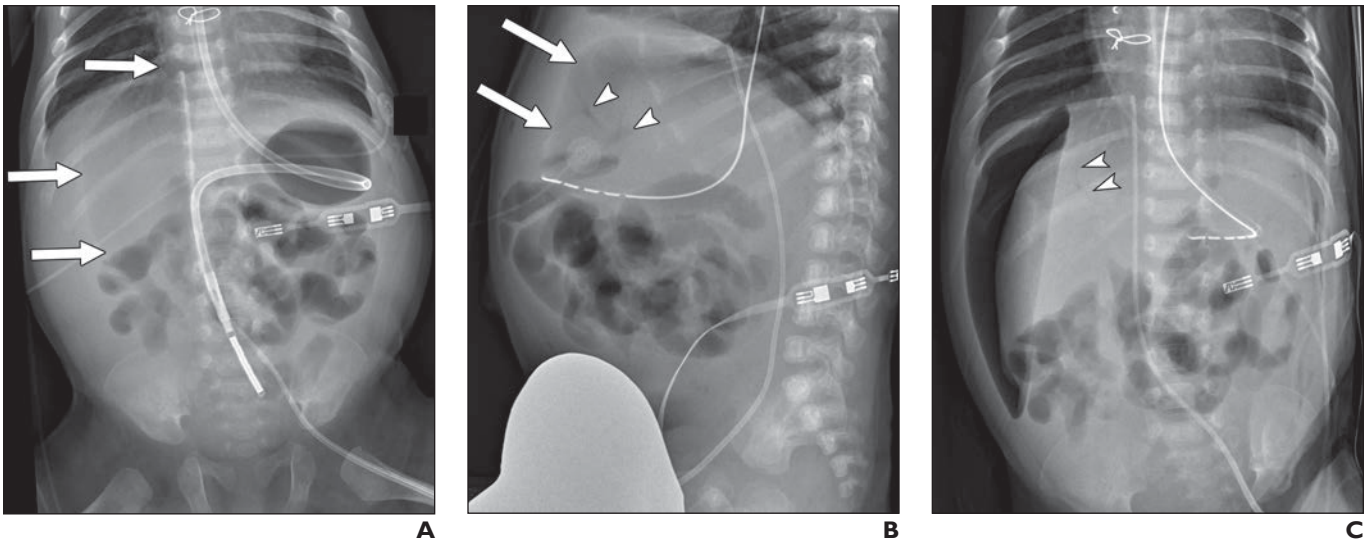

Fig. 4—6-week-old boy with tetralogy of Fallot after placement of Blalock-Taussig shunt with increased irritability that raised clinical concern for possible pneumatosis related to necrotizing enterocolitis, given recent cardiac surgery.
A, Abdominal radiograph obtained with patient in supine position shows unusual low position of weighted tip of enteric tube projected over sacrum at S2, thought to reflect duodenal distortion related to enteric tube presence. Lucency (*arrows*) in right upper quadrant representing pneumoperitoneum was not described.
B and **C,** Subsequent cross-table lateral (**B**) and left lateral decubitus (**C**) abdominal radiographs were obtained a few hours after radiograph shown in **A**, in setting of increased abdominal distention and fever after enteric tube removal. Images show increased pneumoperitoneum (*arrows*, **B**) with interval development of portal venous gas (*arrowheads*, **B** and **C**). Trace subcutaneous gas was also noted along anterior abdominal wall.

Downloaded from www.ajronline.org by 167.61.156.69 on 10/03/17 from IP address 167.61.156.69. Copyright ARRS. For personal use only; all rights reserved

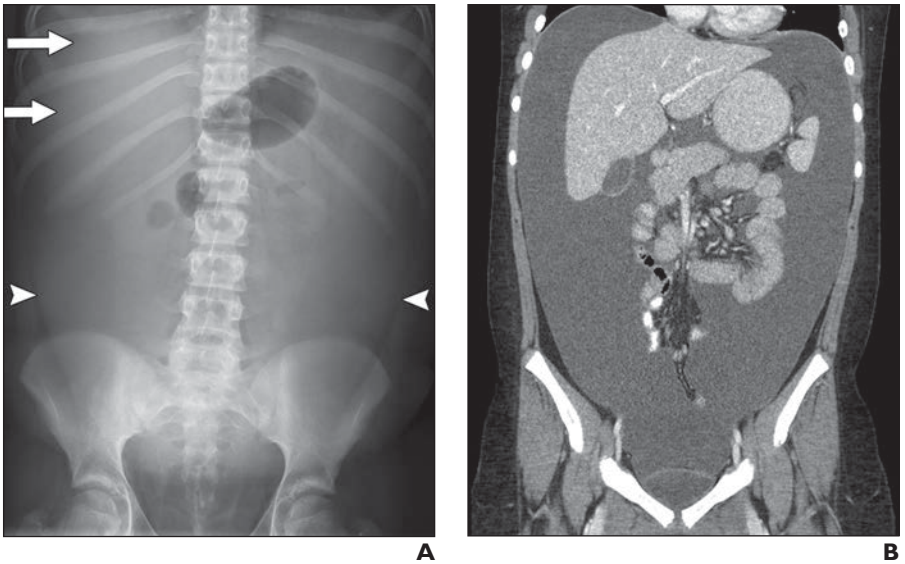

Fig. 5—11-year-old girl with abdominal distention and lethargy occurring 1 month after total colectomy was performed for ulcerative colitis.
A, Abdominal radiograph obtained with patient in supine position shows large-volume ascites with bulging flanks (*arrowheads*), diffuse ground-glass appearance within abdomen, and paucity of bowel gas with centralization of gas-filled bowel loops, which initially were missed. Hellmer sign is present, with medial displacement of lateral edge of liver (*arrows*).
B, Follow-up CT image confirmed radiographic findings. Intraoperative evaluation revealed more than 5 L of chylous ascites.

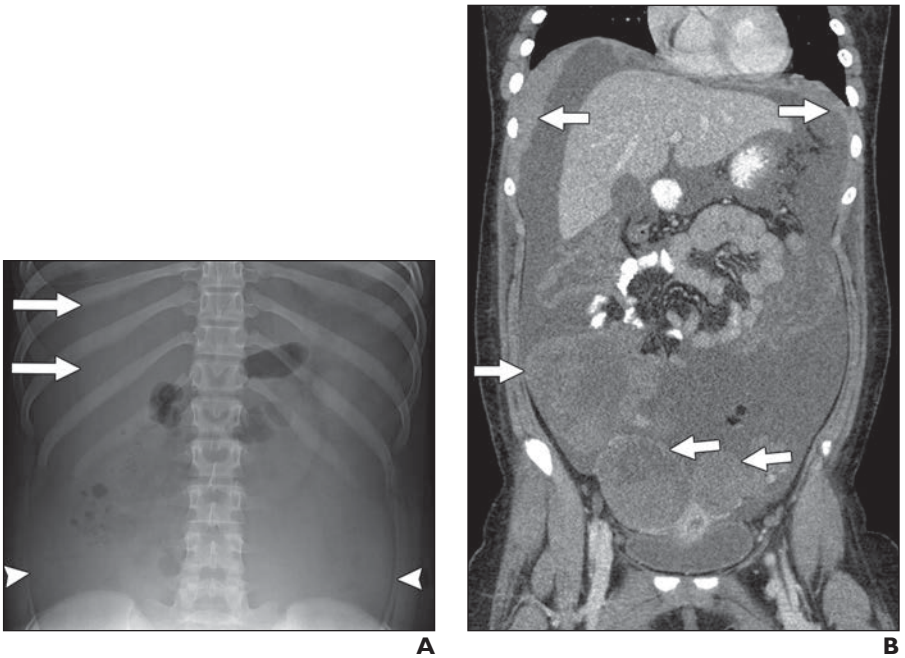

Fig. 6—13-year-old girl with history of constipation and suprapubic pain.
A, Abdominal radiograph obtained with patient in supine position shows paucity of bowel gas with centralization of bowel loops. Prominent bulging of flanks (*arrowheads*) with medial displacement of liver edge (Hellmer sign) (*arrows*) is also shown. Findings were suggestive of large-volume ascites, and ultrasound examination was performed (not shown), which confirmed this finding and also showed multiple abdominal and pelvic soft-tissue masses.
B, Coronal contrast-enhanced CT image of abdomen and pelvis shows multiple heterogeneous soft-tissue masses (*arrows*), consistent with peritoneal implants, in lower abdomen and pelvis as well as along diaphragm bilaterally. Large-volume ascites were again shown. Pathologic findings revealed desmoplastic small round-cell tumor.

Downloaded from www.ajronline.org by 167.61.156.69 on 10/03/17 from IP address 167.61.156.69. Copyright ARRS. For personal use only; all rights reserved

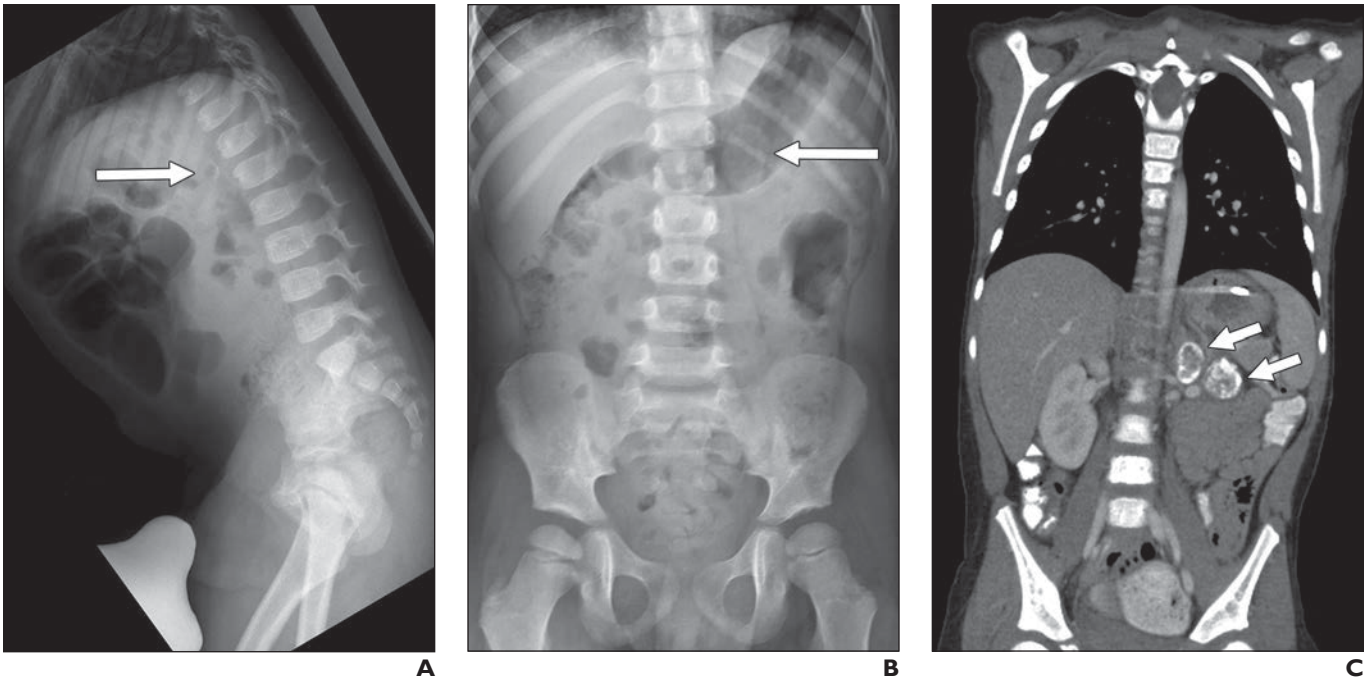

Fig. 7—2-year-old boy who presented with vomiting.
A, Lateral abdominal radiograph obtained as part of abdominal series shows multiple distended bowel loops suggestive of partial obstruction, which resulted from large ileocolic intussusception subsequently diagnosed on abdominal ultrasound. However, small retroperitoneal calcification projecting anterior to T12 vertebral body (*arrow*) was difficult to identify prospectively.
B, Patient presented 2 years later with right lower quadrant pain and constipation. Abdominal radiograph obtained with patient in supine position shows large ovoid well-defined left upper quadrant density (*arrow*) concerning for calcified mass. Abdominal ultrasound exaination (not shown) confirmed presence of large left retroperitoneal mass, which was pathologically proven to be neuroblastoma.
C, Large calcified components (*arrows*) of left retroperitoneal mass centered in region of left adrenal gland were seen on contrast-enhanced CT obtained for staging.

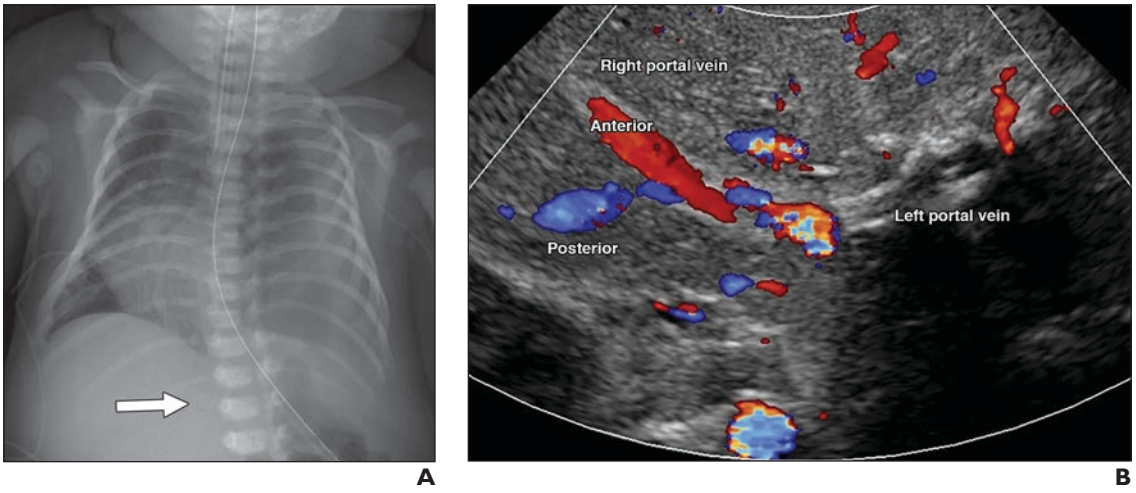

Fig. 8—11-day-old boy with history of repaired congenital diaphragmatic hernia.
A, Chest radiograph shows irregular ill-defined calcification (*arrow*) in upper abdomen to right of L1 vertebral body, which initially was not detected.
B, Color Doppler ultrasound image of liver and proximal portal veins shows complete occlusion of left portal vein with calcified shadowing thrombus. In retrospect, patient had umbilical venous catheter in first days of life, which was presumed cause of thrombosis.

Downloaded from www.ajronline.org by 167.61.156.69 on 10/03/17 from IP address 167.61.156.69. Copyright ARRS. For personal use only; all rights reserved

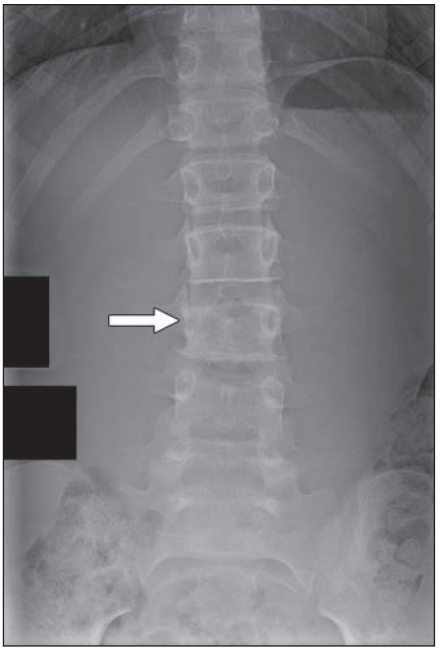

A

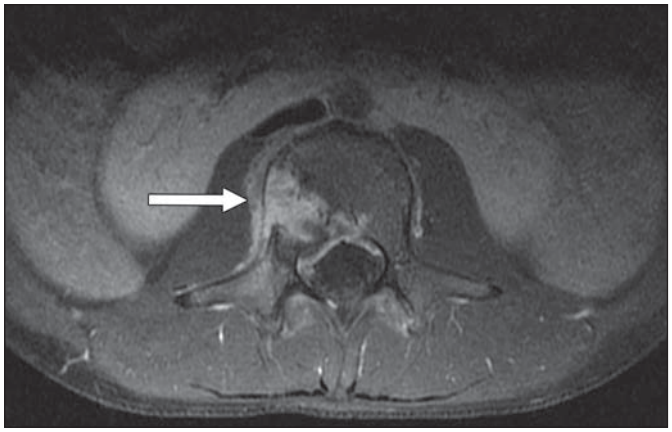

B

Fig. 9—12-year-old girl with intermittent right-sided flank pain for 3 months. **A,** Abdominal radiograph shows subtle lytic lesion (*arrow*) involving right L3 pedicle, which initially was missed on radiographs obtained at outside institution. **B,** Axial contrast-enhanced T1-weighted MR image for continued pain shows enhancing bony lesion (*arrow*) with small adjacent soft-tissue component involving right aspect of L3 vertebral body that extends into right L3 pedicle. Pathologic examination showed Ewing sarcoma. Horseshoe kidney was incidentally noted.

Fig. 10—14-week-old boy born prematurely who had undergone bowel resection for necrotizing enterocolitis. Abdominal radiograph obtained with patient in supine position shows physiologic periosteal reaction along bilateral femoral shafts. Bilateral hip subluxation was not identified prospectively. Surgical clips were present in right lower quadrant at site of bowel resection. Ultrasound examination performed 1 week later (not shown) showed bilateral hip dysplasia (right hip affected more than left hip), as evidenced by abnormally low alpha angles (< 60°) and deficient acetabular coverage (< 50%).

Downloaded from www.ajronline.org by 167.61.156.69 on 10/03/17 from IP address 167.61.156.69. Copyright ARRS. For personal use only; all rights reserved

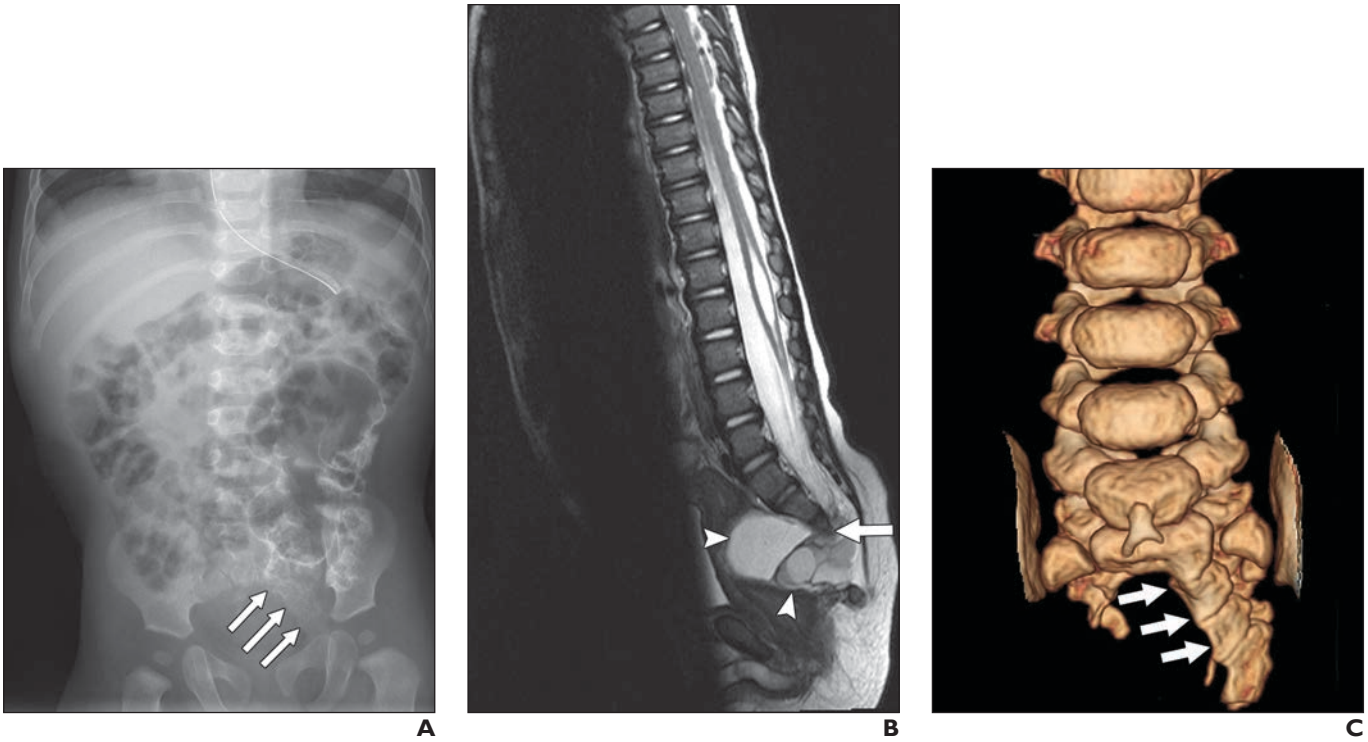

Fig. 11—6-month-old boy with constipation since birth.
A, Frontal abdominal radiograph shows right hemisacral agenesis with crescent-shaped defect (*arrows*) consistent with scimitar sacrum, which was not identified on initial interpretation.
B, Spinal T2-weighted MR image obtained because of concern for tethered cord shows low-lying cord with conus at L4 level. Multiloculated cystic presacral lesion (*arrowheads*) was seen originating from caudal aspect of thecal sac and herniating through right sacral defect (*arrow*), with imaging features suggesting meningocele. Mass caused significant anterior displacement of rectosigmoid colon. Distal cord syringohydromyelia was also noted.
C, Subsequently obtained 3D reformatted CT image of sacrum better shows hemisacral agenesis (*arrows*).

Downloaded from www.ajronline.org by 167.61.156.69 on 10/03/17 from IP address 167.61.156.69. Copyright ARRS. For personal use only; all rights reserved